CASE REPORT*

By Grafton Munroe, D.D.S., Springfield, Ill.

THE case here shown is one exhibiting the result of delayed extraction of deciduous teeth and impacted supernumeraries. The patient is a girl of twelve years of age.

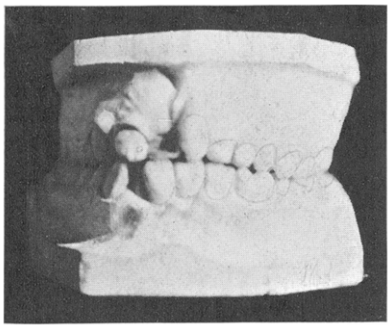

Fig. 1.

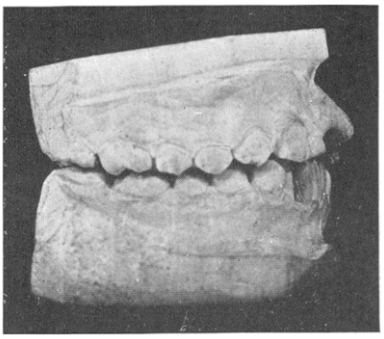

Fig. 2.

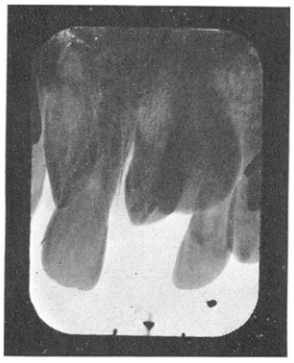

Fig. 3.

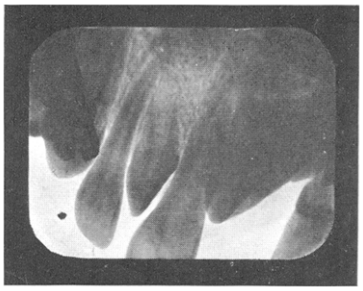

Fig. 4.

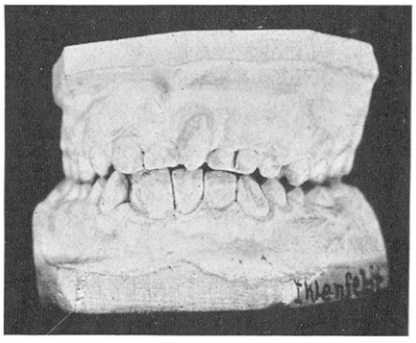

Fig. 5.

*Reported before the American Society of Orthodontists, April 5-7, 1920.

The illustrations show the following condition: Fig. 1, frontal view, shows the maxillary left central (permanent) erupted between the deciduous teeth (central incisors), and standing in torsiversion (about at right angle).

Fig. 2 shows maxillary right lateral and canine in position, but no right central—being a profile view and showing the deciduous central still in place.

Fig. 3, made from x-ray pictures, shows the right central hindered in its eruption by a supernumerary and the supernumerary held back in its eruption by the deciduous central much delayed in extraction. The extraction of the deciduous incisors allowed the permanent teeth to advance so that the supernumeraries could be reached surgically and extracted. After the rotation of the maxillary left central, the permanent lateral and canine came into position, but there developed a wide space between central and lateral, and the cause proved to be another supernumerary, as shown in Fig. 4.

Fig. 5 exhibits a two-thirds profile and front view—with both centrals nearly in normal position—the case still being under care.